

SCHEMA FOR EKG ANALYSIS

I. Measurement of Heart Rate

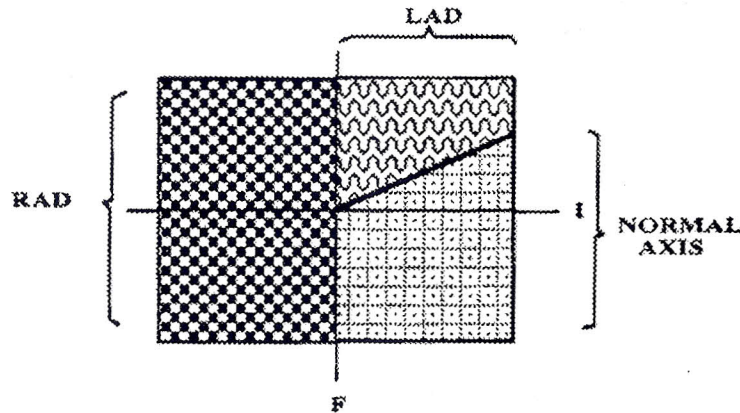
Count the number of R waves in a 6 second strip and x 10.

II. Rhythm

Measure R-R interval; if the difference between the shortest R-R and longest R-R interval is >0.12 , the rhythm is irregular.

III. Determination of Electrical Axis

1. Look at Lead I if more positive than negative, it is either normal axis or left axis deviation (LAD).
2. If Lead I is more negative than positive, it is right axis deviation (RAD).
3. If Lead I is more positive, to determine if there is a normal axis or LAD. Look at Lead aVF, if Lead aVF is more positive, it is a normal axis. If Lead aVF is more negative but < -30 degree it is normal axis, but if it is > -30 degree it is LAD.

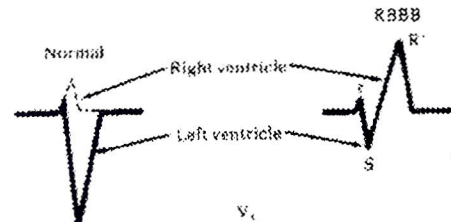


IV. Bundle Branch Block

Bundle branch block is the delay or obstruction of impulse conduction in one of the bundle branches. The blockage may involve in right or left bundle branch, or left anterior or posterior fascicle.

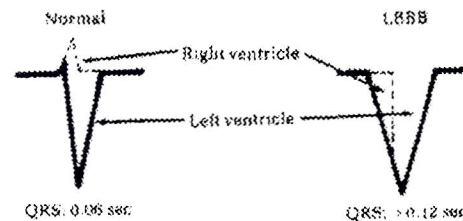
1. Right bundle branch block

- Wide QRS complex $\Rightarrow >0.12$
- Triphasic rsR' or rR' in MCL_1/V_1 ; triphasic qRs in MCL_6/V_6



2. Left bundle branch block

- Wide QRS complex $\Rightarrow >0.12$
- Large Q wave or rS in MCL_1/V_1 ; large R wave in MCL_6/V_6



V. Hemiblock

Hemiblock exists when one of the two branches of the left bundle branch fails to conduct the impulse to the left ventricle.

1. Left anterior hemiblock

- Left axis deviation
- Small Q wave in Lead I; small R wave in Lead III
- Normal QRS duration


2. Left posterior hemiblock

- Right axis deviation
- Small R wave in Lead I; small Q wave in Lead III
- Normal QRS duration

VI. Hypertrophy

1. Right atrial enlargement

- Tall, peaked P waves in II or III > 2.5 mm
- Large initial portion of P wave in V₁
- Negative P wave in aVL



2. Left atrial enlargement

- Terminal portion of the P wave is wider and/or deeper than normal in V₁; i.e. terminal component 1 mm wide and 1mm deep
- The space between peaks of the P wave is more than 0.04 sec. in any lead
- The P wave is 1.6 or more times wider than the P-R segment



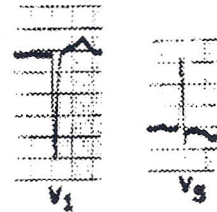
3. Right Ventricular Hypertrophy

- Tall R in V₁ ≥ 7 mm
- Deep S in V₅, V₆
- Right axis deviation
- Downsloping convex S-T segment sloping in V₁, V₂



4. Left Ventricular Hypertrophy

- Deep S in V₁
- Large or tall R in V₅
- Left axis deviation (may not be present)
- The depth (in mm) of S in V₁ + the height (in mm) of R in V₅ > 35 mm
- T wave inversion and asymmetry; i.e. T wave has a gradual downslope and very steep return to the baseline in V₅ or V₆



VII. Identification of Ischemia

1. Most common electrocardiographic changes:

- ST depression of 1 mm with or without flattening or inverted T waves.
- Horizontal ST segment.
- Sharp angled ST-T junction
- U wave inversion

2. Change in Variant Angina, Prinzmetal Angina and Atypical Angina is ST elevation. ST segments return to baseline when angina is relieved

3. Summary of Changes seen in Myocardial Infraction

CHANGES IN MYOCARDIAL INFRACTION		
Location	Indicative Changes	Reciprocal Changes
Inferior	II, III, F	I, L
Anterior	V ₁ - V ₄	II, III, F
Lateral	I, L, V ₅ , V ₆	V ₁ , V ₃ , R
Posterior	V ₁ , V ₂	V ₁ , V ₂


MYOCARDIAL INFRACTION SUMMARY		
Area of Infraction	Lead Changes	Serial Changes
Inferior	II, III, F	ST Elevation T Wave Inversion Q Wave
Posterior	V ₁ , V ₂	ST Depression R/S Ratio > 1 Upright T Wave
Anterior	V ₁ - V ₄	ST Elevation T Wave Inversion Q Wave
Lateral	I, L, V ₅ , V ₆	ST Elevation T Wave Inversion Q Wave
Right Ventricle	V _{3R} , V _{4R}	ST Elevation 1/2 - 1 mm Q Wave

VIII. Miscellaneous Effects

1. Potassium Derangements:

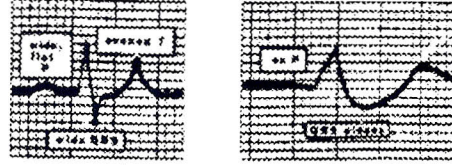
Hypokalemia

- Flat or inverted T wave
- Prominent U wave



Hyperkalemia


- Tall tented T wave
- Flat P wave, wide QRS complex, S wave fusing with T wave, and eventual loss of P wave



2. Calcium Derangements:

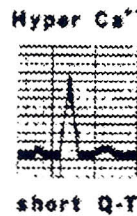
Hypocalcemia

- Prolonged Q - T interval



Hypercalcemia

- Short Q - T interval



3. Digitalis:

Excess digitalis tends to cause

- SA Block
- PAT with Block

- AV Block
- Tachycardia with AV dissociation

Digitalis in toxic amount will stimulate ectopic ventricular foci to discharge and cause

- PVCs
- Ventricular Tachycardia
- Atrial Fibrillation

- Bigeminy, Trigeminy, etc.
- Ventricular Fibrillation

4. Quinidine Effects:

- Notched P wave
- Wide QRS complex
- ST depression

