

# Simvastatin Rescues Rats From Fatal Pulmonary Hypertension by Inducing Apoptosis of Neointimal Smooth Muscle Cells

Toshihiko Nishimura, MD, PhD; Laszlo T. Vaszar, MD; John L. Faul, MD; Guohua Zhao, MD, PhD; Gerald J. Berry, MD; Lingfang Shi, MD; Daoming Qiu, MD; Gail Benson, BS; Ronald G. Pearl, MD, PhD; Peter N. Kao, MD, PhD

**Background**—Pulmonary vascular injury by toxins can induce neointimal formation, pulmonary arterial hypertension (PAH), right ventricular failure, and death. We showed previously that simvastatin attenuates smooth muscle neointimal proliferation and pulmonary hypertension in pneumonectomized rats injected with the alkaloid toxin monocrotaline. The present study was undertaken to investigate the efficacy of simvastatin and its mechanism of reversing established neointimal vascular occlusion and pulmonary hypertension.

**Methods and Results**—Pneumonectomized rats injected with monocrotaline at 4 weeks demonstrated severe PAH at 11 weeks (mean pulmonary artery pressure [mPAP]=42 versus 17 mm Hg in normal rats) and death by 15 weeks. When rats with severe PAH received simvastatin (2 mg · kg<sup>-1</sup> · d<sup>-1</sup> by gavage) from week 11, there was 100% survival and reversal of PAH after 2 weeks (mPAP=36 mm Hg) and 6 weeks (mPAP=24 mm Hg) of therapy. Simvastatin treatment reduced right ventricular hypertrophy and reduced proliferation and increased apoptosis of pathological smooth muscle cells in the neointima and medial walls of pulmonary arteries. Longitudinal transcriptional profiling revealed that simvastatin downregulated the inflammatory genes *fos*, *jun*, and tumor necrosis factor- $\alpha$  and upregulated the cell cycle inhibitor p27Kip1, endothelial nitric oxide synthase, and bone morphogenetic protein receptor type 1a.

**Conclusions**—Simvastatin reverses pulmonary arterial neointimal formation and PAH after toxic injury. (*Circulation*. 2003;108:1640-1645.)

**Key Words:** statins ■ pulmonary heart disease ■ vasculature ■ remodeling

Vascular disease, a leading cause of mortality, represents a pathological response to a variety of stresses, including shear stress and toxic injury (eg, hypercholesterolemia).<sup>1</sup> Primary pulmonary hypertension (PPH), an incurable fatal vascular disease characterized by abnormal proliferation of endothelial and vascular smooth muscle cells within the pulmonary vasculature,<sup>2-4</sup> is seen more commonly in patients who have taken anorexigens.<sup>2</sup> Approximately 50% of patients with familial PPH carry a mutation in the bone morphogenetic protein receptor type 2 (BMPR2), which normally transmits antiproliferative signals and promotes tissue differentiation.<sup>5,6</sup> Patients with acquired forms of pulmonary hypertension show reduced expression of the BMPR type 1a (BMPR1a), a signaling partner of BMPR2.<sup>7</sup> Therefore, a combination of toxic injury and loss of antiproliferative signaling might predispose patients to develop abnormal accumulations of cells within the pulmonary vasculature. Using a rat model of toxic injury to the pulmonary vascular tree, we have shown that the antiproliferative compounds

triptolide, rapamycin, and simvastatin can attenuate the development of pulmonary arterial hypertension (PAH).<sup>8-11</sup>

The HMG-CoA reductase inhibitors, statins, improve cardiovascular outcomes independent of their effects on cholesterol reduction.<sup>12</sup> The immunosuppressive and anti-inflammatory properties of statins<sup>13</sup> may contribute to the improved survival of patients with atherosclerosis.<sup>12,14</sup> Statins can suppress endothelial and vascular smooth muscle cell inflammatory and proliferative responses to injury.<sup>15-17</sup> These effects involve inhibition of isoprenylation of rho- and rac-family GTPases that couple growth factor receptors to the intracellular MAP/ERK kinase signaling pathways and induction of the cell cycle inhibitor p27<sup>Kip1</sup>.<sup>16,17</sup> Statins also improve endothelium-dependent relaxation through mechanisms that involve induction of endothelial nitric oxide synthase (eNOS) and nitric oxide production.<sup>18,19</sup>

We recently demonstrated that simvastatin attenuates vascular smooth muscle neointimal proliferation and pulmonary hypertension in pneumonectomized, monocrotaline-injected

Received January 16, 2003; de novo received April 3, 2003; revision received May 20, 2003; accepted May 21, 2003.

From the Division of Pulmonary and Critical Care Medicine (T.N., L.T.V., J.L.F., G.Z., L.S., D.Q., P.N.K.) and the Departments of Pathology (G.J.B.) and Anesthesiology (G.B., R.G.P.), Stanford University Medical Center, Stanford, Calif.

Correspondence to Peter N. Kao, MD, PhD, Pulmonary and Critical Care Medicine, Stanford University Medical Center, Stanford, CA 94305-5236. E-mail peterkao@stanford.edu

© 2003 American Heart Association, Inc.

*Circulation* is available at <http://www.circulationaha.org>

DOI: 10.1161/01.CIR.0000087592.47401.37

rats.<sup>11</sup> On the basis of our discovery of the efficacy of simvastatin in preventing neointimal pulmonary vascular disease in this model, we wanted to examine whether simvastatin could reverse established severe pulmonary hypertension after toxic injury and improve survival.

## Methods

### Study Design

All animals received humane care, and the study was approved by the Stanford Panel on Laboratory Animal Care. Adult Sprague Dawley rats were obtained from Charles River Laboratories (Wilmington, Mass). Pneumonectomy was performed as previously described,<sup>8,9</sup> and monocrotaline (60 mg/kg) was injected subcutaneously on day 28.

### Treatment Groups

Rats (n=24) were randomized to receive simvastatin (n=12) or vehicle (n=6) by daily gavage at week 11. Four groups were studied: the rats in group PMV<sub>0w</sub> (n=6) were killed at week 11. Group PMV<sub>2w</sub> (vehicle group, n=6) received a vehicle from week 11 to 13. Group PMS<sub>2w</sub> (n=6) received simvastatin (2 mg · kg<sup>-1</sup> · d<sup>-1</sup>) from week 11 to week 13. Group PMS<sub>6w</sub> (n=6) received simvastatin (2 mg · kg<sup>-1</sup> · d<sup>-1</sup>) from week 11 to week 17. Six additional rats were studied as a control group without any intervention. Hemodynamic measurements, organ analyses, and histological quantification of neointimal vascular occlusion were performed as previously described.<sup>8,9</sup>

### Immunohistochemistry

Proliferation was analyzed by use of a monoclonal antibody against proliferating cell nuclear antigen (PCNA; 1:100, DAKO), and in situ apoptosis was analyzed by terminal deoxynucleotidyl transferase-mediated dUTP-biotin nick end-labeling (TUNEL; TACS 2 TdT, Trevigen).

### Statistical Analysis

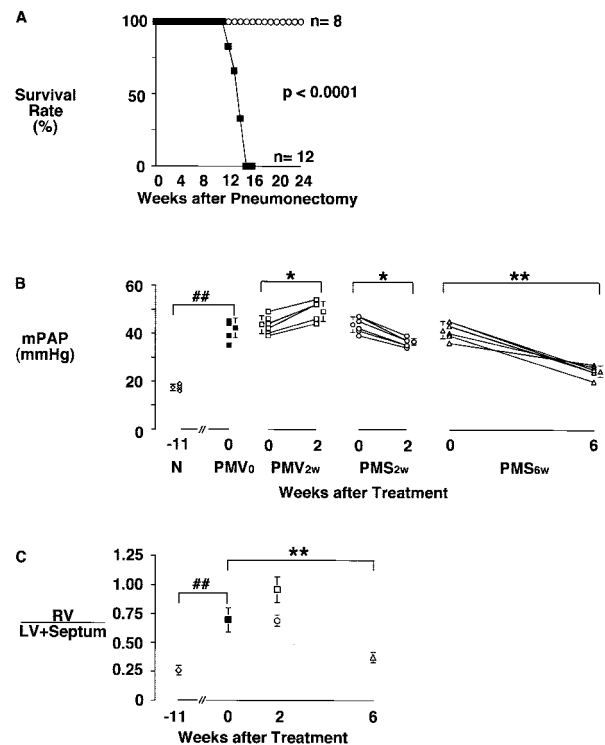
Data are presented as mean ± SD. First, the data from normal rats were compared with group PMV<sub>0</sub> (the disease model) by use of Student's *t* test (statistical significance was indicated by a value of *P* < 0.05). Next, groups PMV<sub>0</sub>, PMV<sub>2w</sub>, PMS<sub>2w</sub>, and PMS<sub>6w</sub> were analyzed by 2-way ANOVA. A value of *P* < 0.05 was considered statistically significant.

### Gene Array Studies and Bioinformatics

Lung gene expression was analyzed in 3 individual rats at each experimental condition. Radiolabeled cDNA probes were generated from 50 μg of total RNA extracted from homogenized lungs, then Southern-hybridized to nylon arrays containing 1176 genes (Atlas Rat 1.2 Array Model 7854-1, Clontech). Signals were quantified by use of a Cyclone phosphorimager and Optiquant 3.0 software (Packard Instruments). By use of Microsoft Excel, the expression values for each gene at each time point were median-centered, averaged, and logarithmically transformed. We processed the average of replicates for each time point by average-linkage hierarchical clustering and k-means analysis using the J-Express software package (Bjarte Dysvik, University of Bergen, Norway).<sup>20</sup>

## Results

Monocrotaline undergoes hepatic metabolism in rats into monocrotaline pyrrole, which produces toxic injury to the pulmonary endothelium through covalent reactions with cytosolic and cytoskeletal proteins.<sup>21</sup> The combination of pneumonectomy and monocrotaline administration in rats leads to severe PAH with neointimal formation, right ventricular hypertrophy, and eventual death.<sup>8,9,22,23</sup>



**Figure 1.** Simvastatin confers 100% survival advantage and reverses established hypertensive pulmonary vascular disease. Pneumonectomized, monocrotaline-injected rats underwent hemodynamic measurements at 11 weeks (n=24) and were then randomized to receive vehicle (n=6) or treatment with simvastatin (2 mg · kg<sup>-1</sup> · d<sup>-1</sup> by gavage, n=12). Another 6 rats were used for RV/LV+S ratio study. A, Kaplan-Meier survival plot: Rats (n=20) were randomized to receive vehicle (control) or simvastatin rescue treatment at 11 weeks. Control rats that received vehicle all died of progression of pulmonary hypertension by 15 weeks (n=12, filled squares), whereas all rats rescued with simvastatin treatment survived and underwent scheduled measurements at 23 weeks (n=8, open circles). B, Mean pulmonary arterial pressure: time course of development and regression of pulmonary hypertension in control and simvastatin-treated rats. C, Right ventricular hypertrophy was demonstrated by RV/LV+S ratio in control and simvastatin-treated rats. ##*P* < 0.01 by Student's *t* test; \**P* < 0.05 by ANOVA; \*\**P* < 0.01 by ANOVA.

### Simvastatin Reversed Established PAH

#### Survival Analysis

When we injected rats with monocrotaline 4 weeks after pneumonectomy, pulmonary hypertension developed at 8 weeks and continued to increase until death by 15 weeks. In this study, rats were randomized to receive vehicle or simvastatin (2 mg · kg<sup>-1</sup> · d<sup>-1</sup> by oral gavage) beginning at 11 weeks (week 0). Rats that received vehicle for 2 weeks lost weight and scarcely moved before death by 15 weeks (0% survival) (Fig. 1A, filled squares). In contrast, all simvastatin-treated rats were spontaneously active, feeding and gaining weight from 11 weeks onward and showing no mortality at 15 weeks (Fig. 1A, open circles). Thus, simvastatin conferred a 100% survival advantage compared with rats that received vehicle (*P* < 0.001).

#### Hemodynamics

Rats (n=24) consistently developed severe PAH by 11 weeks (mean pulmonary artery pressure [mPAP] = 42 ± 2 mm Hg, right ventricular systolic pressure [RVSP] = 59 ± 4 mm Hg)

(Fig. 1B, filled squares) at the time of randomization to vehicle or simvastatin treatment (week 0). Seventeen percent ( $n=1$ ) of rats randomized to receive vehicle ( $n=6$ ), group  $PMV_{2w}$ , died by 13 weeks, and the remainder were killed for hemodynamic measurements that demonstrated progression of severe PAH (mPAP= $53\pm 2$  mm Hg, RVSP= $72\pm 5$  mm Hg) (Fig. 1B, open squares).

All simvastatin-treated rats survived until they were killed at 2 weeks, group  $PMS_{2w}$  (mPAP= $36\pm 2$  mm Hg, RVSP= $53\pm 7$  mm Hg) (Figure 1B, open circles) and 6 weeks, group  $PMS_{6w}$  (mPAP= $24\pm 3$  mm Hg, RVSP= $34\pm 3$  mm Hg) (Figure 1B, open triangles). In every rat, simvastatin reversed PAH and normalized the mean pulmonary pressures after 6 weeks (Figure 1B, open triangles) and 13 weeks ( $22\pm 3$  mm Hg, RVSP= $30\pm 3$  mm Hg).

### Right Ventricular Hypertrophy

The right ventricular weight to left ventricular plus septum weight ratio (RV/LV+S) in normal rats is  $0.25\pm 0.03$ . By 11 weeks, pulmonary hypertensive rats demonstrated significant right ventricular hypertrophy (RV/LV+S= $0.71\pm 0.1$ ) (Fig. 1C, closed squares). Rats that received vehicle for 2 weeks, group  $PMV_{2w}$ , demonstrated progression of right ventricular hypertrophy (RV/LV+S= $0.92\pm 0.1$ ) (Figure 1C, open boxes). Simvastatin prevented progression and reversed established right ventricular hypertrophy at 2 weeks, group  $PMS_{2w}$  (RV/LV+S= $0.69\pm 0.05$ ) (Figure 1C, open circle); 6 weeks, group  $PMS_{6w}$  (RV/LV+S= $0.38\pm 0.05$ ) (Figure 1C, open triangle); and 13 weeks (RV/LV+S= $0.28\pm 0.03$ ).

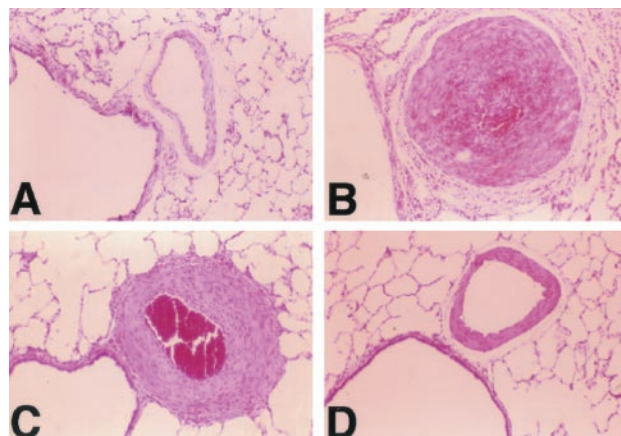
### Histopathology: Simvastatin Is Associated With Decreased Medial Hypertrophy and Neointimal Occlusion and Increased Apoptosis of Vascular Smooth Muscle Cells

#### Medial Hypertrophy and Neointimal Formation in Large Peribronchial Pulmonary Arteries

Prominent medial wall hypertrophy and neointimal formation are evident in muscular pulmonary arteries from diseased rats that received vehicle (group  $PMV_{2w}$ ) (Fig. 2B versus 2A). Intimal injury with endothelialitis was noted in many of the affected arteries. The thickened medial layer displayed smooth muscle proliferation admixed with pyknotic cells and acute inflammatory cells. The perivascular tissue spaces contained increased numbers of inflammatory cells embedded in a granulation tissue matrix. Plexiform lesions within muscular pulmonary arteries were not observed. In contrast, rats treated with simvastatin (group  $PMS_{2w}$ ) demonstrated decreased medial hypertrophy (Fig. 2C versus 2B), and rats treated with simvastatin for 6 weeks (group  $PMS_{6w}$ ) showed resolution of the inflammation and near complete patency of the pulmonary arteries (Fig. 2D).

#### Simvastatin Attenuated Proliferation and Induced Apoptosis of Vascular Smooth Muscle Cells

Neointimal formation within muscular pulmonary arteries was prominent in rats that received vehicle (group  $PMV_{2w}$ ) but absent in rats treated with simvastatin (group  $PMS_{2w}$ ) (Fig. 3A versus 3B). Large peribronchial muscular pulmonary arteries from group  $PMV_{2w}$  rats demonstrated prominent PCNA-positive-staining cells in the neointima and medial



**Figure 2.** Simvastatin reverses pulmonary artery medial hypertrophy in muscular pulmonary arteries. A, Normal peribronchial muscular pulmonary artery in Normal rat. B, Prominent thickened medial layer and neointimal lesion in control rats that received vehicle for 2 weeks (group  $PMV_{2w}$ ). C, Less thickened medial layer and neointimal lesion in rats rescued by simvastatin treatment for 2 weeks (group  $PMS_{2w}$ ). D, Regression of thickened medial wall in rats rescued by simvastatin treatment for 6 weeks (group  $PMS_{6w}$ ). Hematoxylin and eosin staining; magnification  $\times 40$ .

wall (Fig. 3C). In contrast, simvastatin-treated rats (group  $PMS_{2w}$ ) showed rare PCNA-positive-staining cells (Fig. 3D).

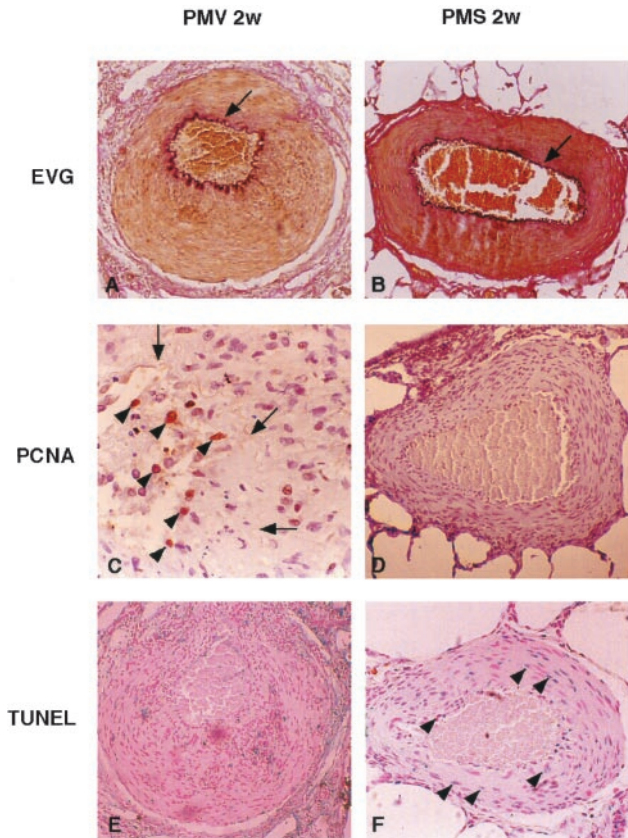
The ability of simvastatin to induce regression of medial hypertrophy (Fig. 2, C and D), neointimal formation (Figure 3B), and pulmonary hypertension (Figure 1B) was likely to involve apoptosis of vascular lining cells. We demonstrated increased numbers of TUNEL-positive apoptotic nuclei in the medial walls and neointima of pulmonary arteries of rats treated with simvastatin (group  $PMS_{2w}$ ) (Fig. 3F) compared with rats that received vehicle (group  $PMV_{2w}$ ) (Fig. 3E). Thus, in addition to an antiproliferative effect, simvastatin treatment promotes apoptosis of vascular smooth muscle cells in this model of PAH.

#### Quantitative Analysis of Neointimal Luminal Obstruction in Small Pulmonary Arteries

We performed a quantitative analysis of neointimal luminal obstruction on 25 consecutive small pulmonary arteries from each rat in the groups (Fig. 4). The distribution of the vascular lesions and an average vascular occlusion score (VOS) between 0 and 2 are presented (Fig. 4E). The VOS of 1.85 at 11 weeks (group  $PMV_{0w}$ ) increased to 1.95 in rats that received vehicle for 2 weeks (group  $PMV_{2w}$ ) (Fig. 4B), and these VOSs were similar to the VOS of  $1.98\pm 0.02$  that we observed in the 35-day model of hypertensive pulmonary vascular disease.<sup>8,9</sup> Just 2 weeks of simvastatin treatment decreased the VOS to 1.34 (group  $PMS_{2w}$ ) (Fig. 4C), and 6 weeks of treatment further decreased the VOS to 0.83 (group  $PMS_{6w}$ ) (Fig. 4D). At 13 weeks of treatment, the VOS was 0.65 (group  $PMS_{13w}$ ), indicating near complete reversal of the neointimal vascular occlusion by simvastatin treatment.

We previously used immunohistochemical staining for  $\alpha$ -smooth muscle actin and electron microscopy to demonstrate that the neointimal lesions in this disease model consist predominantly of smooth muscle cells.<sup>11</sup>



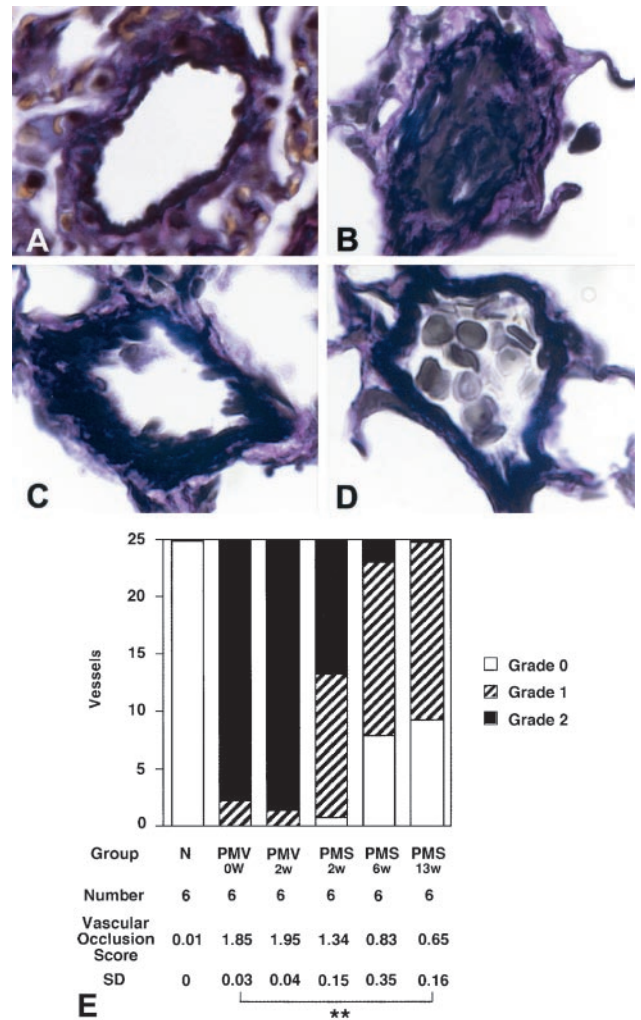


**Figure 3.** Simvastatin suppresses proliferation and induces apoptosis of pulmonary artery smooth muscle cells. A, C, and E, Histology from control rats that received vehicle for 2 weeks (group PMV<sub>2w</sub>); B, D, and F, histology from rats rescued by simvastatin treatment for 2 weeks (group PMS<sub>2w</sub>). A and B, Elastin van Gieson (EVG) staining of peribronchial muscular pulmonary artery; magnification  $\times 40$ . A, Rats in PMV<sub>2w</sub> demonstrated a prominent thickened medial wall and neointimal formation B, Rats in PMS<sub>2w</sub> demonstrated a less thickened medial wall and little neointimal formation. Arrows show internal elastic lamina. C and D, Proliferating vascular cells were stained by PCNA immunohistochemical staining (magnification: C,  $\times 100$ ; D,  $\times 40$ ). Brown-staining nuclei are PCNA-positive cells that are prominent in neointimal lesions in group PMV<sub>2w</sub> but are rare in group PMS<sub>2w</sub>. Arrows, internal elastic lamina. Arrowheads, PCNA-positive cells. E and F, Apoptosis in vascular cells is shown by TUNEL staining; magnification  $\times 40$ . F, Blue-stained nuclei are TUNEL-positive cells that are more prominent in PMS<sub>2w</sub> than PMV<sub>2w</sub>. Arrowheads mark TUNEL-positive cells undergoing apoptosis.

**Large-Scale Transcriptional Analysis of Hypertensive Pulmonary Vascular Disease**

We compared lung gene expression profiles between 4 groups of rats (Fig. 5): normal rats (week -11, open bars), diseased rats at 11 weeks (week 0, solid bars), group PMV<sub>2w</sub> (solid bars), and group PMS<sub>2w</sub> (shaded bars). We separately analyzed lung mRNA expression from 3 individual rats in each group, and this helped us to recognize variability of gene expression and recognize patterns associated with disease progression and reversal by simvastatin. Of the 1176 genes analyzed by use of the Clontech ATLAS arrays and J-express processing software,<sup>20</sup> we present those genes with prominent divergence of expression between groups PMV<sub>2w</sub> and PMS<sub>2w</sub> (Fig. 5).

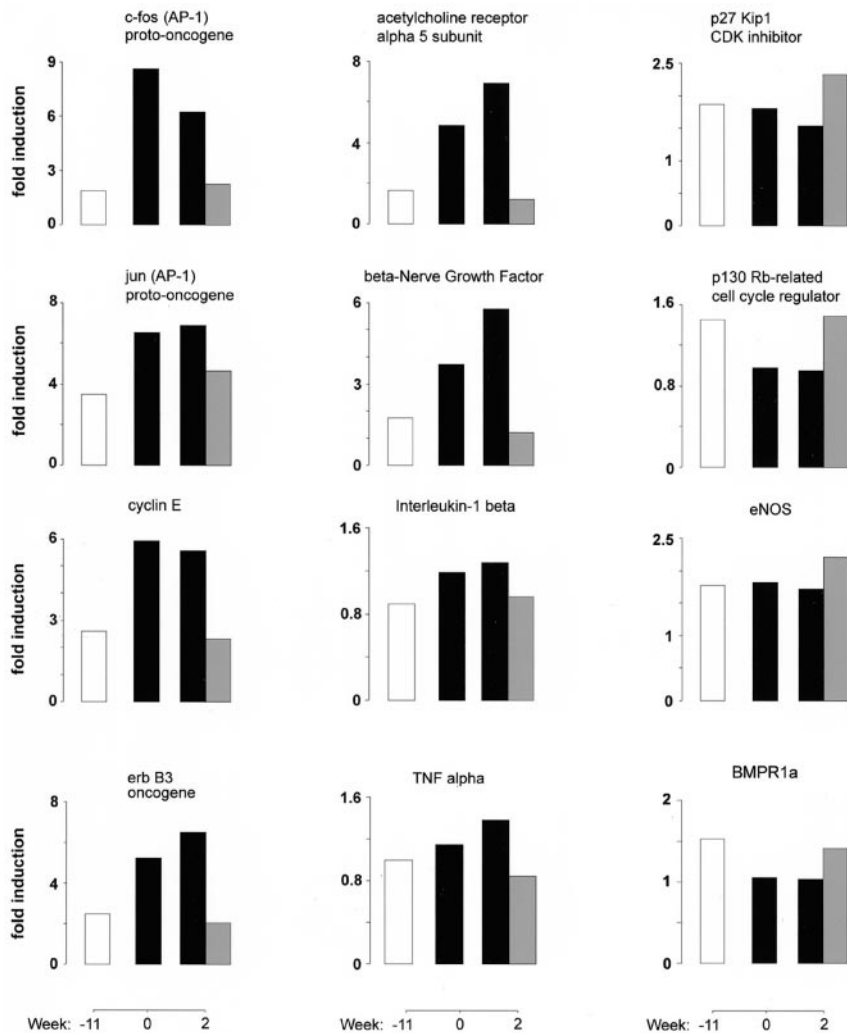
Our disease model was characterized by progressive increases in the expression of numerous inflammatory genes, including the



**Figure 4.** Simvastatin reverses neointimal vascular occlusion. VOS is average score for 25 consecutive intra-acinar pulmonary arteries. Vessels were assessed for neointimal proliferative lesions and scored: grade 0, no evidence of neointimal formation; grade 1,  $< 50\%$  luminal occlusion; grade 2,  $> 50\%$  luminal occlusion. A-D, Elastin van Gieson stain; magnification  $\times 600$ . A, Normal rat intra-acinar artery without evidence of neointimal proliferation (grade 0). B, Grade 2 neointimal lesion ( $> 50\%$  luminal occlusion) in group PMV<sub>2w</sub>. C, Grade 1 lesion ( $< 50\%$  luminal occlusion) in group PMS<sub>2w</sub>. D, Grade 0 lesion in group PMS<sub>6w</sub>. E, Grades of vascular occlusion in lungs of groups N (normal), PMV<sub>0w</sub>, PMV<sub>2w</sub>, PMS<sub>2w</sub>, PMS<sub>6w</sub>, and PMS<sub>13w</sub>. \*\* $P < 0.01$  by ANOVA.

transcriptional regulators of the activator protein-1 family, c-fos and jun, and the cytokines interleukin- $1\beta$  and tumor necrosis factor- $\alpha$  (Fig. 5). Other notable genes induced during disease progression were the tyrosine kinase growth factor receptor erb-B3 and cyclin E and the neuronal signaling molecules acetylcholine receptor subunit  $\alpha 5$  and  $\beta$ -nerve growth factor (Fig. 5). Each of these genes that increase during disease progression was inhibited by simvastatin treatment, which supports the efficacy of the anti-inflammatory mechanisms of statins in pulmonary vascular disease after toxic injury.

Several genes show a reciprocal pattern of expression and were induced by simvastatin treatment (Fig. 5, right column). Notable among these genes was the induction of the cyclin-dependent kinase inhibitor p27Kip1 and the cell cycle regulator



**Figure 5.** Transcriptional profiling of gene expression in neointimal pulmonary vascular disease and reversal by simvastatin. Selected genes from ATLAS array with divergent expression in control group PMV<sub>2w</sub> (vehicle-treated rats, black bars) compared with simvastatin-treated group PMS<sub>2w</sub> (gray bars). Expression levels in normal lungs (open bars) are shown for comparison. Genes induced during progression of pulmonary vascular disease that are suppressed by simvastatin treatment include inflammatory transcriptional regulators of AP-1 family, c-fos and jun, and cytokines interleukin-1 $\beta$  and tumor necrosis factor (TNF)- $\alpha$  (left and central columns). Genes with diminished expression in pulmonary vascular disease that were restored or induced by simvastatin rescue treatment include antiproliferative regulators p27Kip1 and p130 retinoblastoma (Rb)-related protein and eNOS (right column). Values represent averages of median-centered replicates for any given time point, so that an expression level of 1 represents average of median gene intensities of replicates for given experimental time point.

p130 retinoblastoma (Rb)-related protein. BMPR1a expression was reduced during disease progression and restored by simvastatin treatment. Simvastatin induction of eNOS mRNA in this disease model correlates with our previous findings.<sup>11</sup>

### Discussion

We showed recently that simvastatin attenuated the development of pulmonary hypertension with neointimal formation in rats.<sup>11</sup> Here, we demonstrate that simvastatin conferred a 100% survival advantage on rats with established pulmonary hypertension, reversed established PAH, and was associated with reductions in pulmonary arterial neointimal occlusion, medial hypertrophy, and right ventricular hypertrophy.

Neointimal pulmonary vascular occlusive lesions, consisting of proliferating smooth muscle cells and bearing similarities to the pathological lesions in human PPH,<sup>4</sup> are evident in rats after the combination of pneumonectomy with monocrotaline injection.<sup>8,9,11,22,23</sup> We hypothesize that a combination of compensatory lung growth after pneumonectomy, hemodynamic factors, and endothelial injury by monocrotaline pyrrole combine to produce this neointimal pulmonary vascular disease.<sup>23</sup> Delaying the injection of monocrotaline from 1 to 4 weeks after pneumonectomy slowed the rate of development of PAH and allowed us to document severe

PAH before initiation of vehicle or rescue simvastatin treatment. To the best of our knowledge, this study is the first to demonstrate reversal of severe PAH associated with reduction of neointimal formation in both large peribronchial pulmonary arteries and small acinar pulmonary arteries.

The data suggest that simvastatin exerted potent effects on vascular wall proliferation and inflammation. Interestingly, the dose of simvastatin we used as rescue therapy in this study ( $2 \text{ mg} \cdot \text{kg}^{-1} \cdot \text{d}^{-1}$ ) is considerably lower than that used in previous animal studies of its cardiovascular effects. Higher doses of simvastatin ( $5$  to  $40 \text{ mg} \cdot \text{kg}^{-1} \cdot \text{d}^{-1}$ ) attenuated neointimal formation in injured carotid arteries<sup>15,17</sup> and induced regression of cardiac hypertrophy.<sup>24,25</sup>

Simvastatin suppressed the abnormal proliferation of vascular smooth muscle cells (reduced PCNA-positive staining) and induced apoptosis of pathological vascular smooth muscle cells (increased TUNEL staining) in vivo. In this disease model, simvastatin induced expression of the cell cycle inhibitor p27<sup>Kip</sup>, in agreement with the mechanisms of simvastatin attenuation of aortic smooth muscle cell proliferation in vitro.<sup>16</sup> We showed that simvastatin induced apoptosis of pathological vascular smooth muscle cells in vivo, in agreement with the finding that lipophilic statins induced apoptosis of vascular smooth muscle cells in vitro through downregu-

lation of bcl-2 and rho prenylation.<sup>26,27</sup> We demonstrate here, as previously,<sup>11</sup> that simvastatin upregulated eNOS mRNA expression in vivo, and this may correlate with improved pulmonary endothelial function.

Our model of neointimal pulmonary vascular disease showed histological evidence of inflammation, and this finding is supported by our gene array expression analysis, which demonstrated increased expression of inflammatory genes and inflammatory transcriptional regulators of the AP-1 family, fos and jun. Simvastatin suppressed the inflammatory component on histology in addition to normalizing the vascular morphology. Simvastatin inhibited AP-1 and the expression of AP-1-regulated inflammatory cytokines in this in vivo model of pulmonary vascular disease. These results agree with in vitro studies that showed that lovastatin suppressed fos and jun protein expression and cellular proliferation in renal proximal tubule cells<sup>28</sup> and smooth muscle cells.<sup>29</sup>

Simvastatin reverses neointimal vascular occlusion and fatal pulmonary hypertension in this rat model through antiproliferative, anti-inflammatory, and proapoptotic effects on vascular smooth muscle cells. Differences exist between this rat model of pulmonary vascular disease and human PPH, most notably the rate of disease progression (months versus years), the absence of plexiform lesions in rats, and the absence of genetic mutations in BMPR2. Du et al<sup>7</sup> proposed that a common feature linking all forms of human pulmonary hypertension is inactivation of BMPR signaling, either through genetic mutations in BMPR2 or through suppression of BMPR1a. In support of this concept, our gene array analysis revealed suppression of BMPR1a expression in diseased rats. Remarkably, simvastatin restored BMPR1a expression to a level close to that in normal rats. How simvastatin may restore BMPR1a expression in diseased lungs represents an important question for future investigations.

Recognizing that human hypertensive pulmonary vascular disease represents a disease of excessive smooth muscle cell proliferation and that simvastatin effectively reverses neointimal vascular occlusion in a rat model of pulmonary hypertension, we anticipate that statins may prove effective as antiproliferative therapies for human pulmonary vascular disease.

### Acknowledgments

This study was supported by a gift from the Donald E. and Delia B. Baxter Foundation and National Institutes of Health grants AI-39624 and HL-62588 to Dr Kao. We thank Professor Yoshinori Fujii, Department of Statistics, Stanford University, for statistical advice and Gail V. Benson for technical assistance.

### References

- Carmeliet P. Mechanisms of angiogenesis and arteriogenesis. *Nat Med.* 2000;6:389–395.
- Fishman AP, Fishman MC, Freeman BA, et al. Mechanisms of proliferative and obliterative vascular diseases: insights from the pulmonary and systemic circulations. NHLBI Workshop summary. *Am J Respir Crit Care Med.* 1998;158:670–674.
- Tuder RM, Voelkel NF. Pulmonary hypertension and inflammation. *J Lab Clin Med.* 1998;132:16–24.
- Yi ES, Kim H, Ahn H, et al. Distribution of obstructive intimal lesions and their cellular phenotypes in chronic pulmonary hypertension: a morphometric and immunohistochemical study. *Am J Respir Crit Care Med.* 2000;162:1577–1586.
- Deng Z, Morse JH, Slager SL, et al. Familial primary pulmonary hypertension (gene PPH1) is caused by mutations in the bone morphogenetic protein receptor-II gene. *Am J Hum Genet.* 2000;67:737–744.
- Lane KB, Machado RD, Pauculo MW, et al. Heterozygous germline mutations in BMPR2, encoding a TGF-beta receptor, cause familial primary pulmonary hypertension. The International PPH Consortium. *Nat Genet.* 2000;26:81–84.
- Du L, Sullivan CC, Chu D, et al. Signaling molecules in nonfamilial pulmonary hypertension. *N Engl J Med.* 2003;348:500–509.
- Faul JL, Nishimura T, Berry GJ, et al. Triptolide attenuates pulmonary arterial hypertension and neointimal formation in rats. *Am J Respir Crit Care Med.* 2000;162:2252–2258.
- Nishimura T, Faul JL, Berry GJ, et al. 40-O-(2-Hydroxyethyl)-rapamycin attenuates pulmonary arterial hypertension and neointimal formation in rats. *Am J Respir Crit Care Med.* 2001;163:498–502.
- Newman JH, Lane KB. Hypertensive pulmonary vascular disease: dawn of the age of prevention? *Am J Respir Crit Care Med.* 2000;162:2020–2021.
- Nishimura T, Faul JL, Berry GJ, et al. Simvastatin attenuates smooth muscle neointimal proliferation and pulmonary hypertension in rats. *Am J Respir Crit Care Med.* 2002;166:1403–1408.
- Maron DJ, Fazio S, Linton MF. Current perspectives on statins. *Circulation.* 2000;101:207–213.
- Kwak B, Mulhaupt F, Myit S, et al. Statins as a newly recognized type of immunomodulator. *Nat Med.* 2000;6:1399–1402.
- Bustos C, Hernandez-Presa MA, Ortego M, et al. HMG-CoA reductase inhibition by atorvastatin reduces neointimal inflammation in a rabbit model of atherosclerosis. *J Am Coll Cardiol.* 1998;32:2057–2064.
- Soma MR, Donetti E, Parolini C, et al. HMG CoA reductase inhibitors: in vivo effects on carotid intimal thickening in normocholesterolemic rabbits. *Arterioscler Thromb.* 1993;13:571–578.
- Laufs U, Marra D, Node K, et al. 3-Hydroxy-3-methylglutaryl-CoA reductase inhibitors attenuate vascular smooth muscle proliferation by preventing rho GTPase-induced down-regulation of p27(Kip1). *J Biol Chem.* 1999;274:21926–21931.
- Indolfi C, Cioppa A, Stabile E, et al. Effects of hydroxymethylglutaryl coenzyme A reductase inhibitor simvastatin on smooth muscle cell proliferation in vitro and neointimal formation in vivo after vascular injury. *J Am Coll Cardiol.* 2000;35:214–221.
- Laufs U, Fata VL, Liao JK. Inhibition of 3-hydroxy-3-methylglutaryl (HMG)-CoA reductase blocks hypoxia-mediated down-regulation of endothelial nitric oxide synthase. *J Biol Chem.* 1997;272:31725–31729.
- Kureishi Y, Luo Z, Shiojima I, et al. The HMG-CoA reductase inhibitor simvastatin activates the protein kinase Akt and promotes angiogenesis in normocholesterolemic animals. *Nat Med.* 2000;6:1004–1010.
- Dysvik B, Jonassen I. J-express: exploring gene expression data using Java. *Bioinformatics.* 2001;17:369–370.
- Lame MW, Jones AD, Wilson DW, et al. Protein targets of monocrotaline pyrrole in pulmonary artery endothelial cells. *J Biol Chem.* 2000;275:29091–29099.
- Okada K, Tanaka Y, Bernstein M, et al. Pulmonary hemodynamics modify the rat pulmonary artery response to injury: a neointimal model of pulmonary hypertension. *Am J Pathol.* 1997;151:1019–1025.
- Nishimura T, Faul JL, Berry GJ, et al. Effect of a surgical aortocaval fistula on monocrotaline-induced pulmonary hypertension. *Crit Care Med.* 2003;31:1213–1218.
- Indolfi C, Di Lorenzo E, Perrino C, et al. Hydroxymethylglutaryl coenzyme A reductase inhibitor simvastatin prevents cardiac hypertrophy induced by pressure overload and inhibits p21ras activation. *Circulation.* 2002;106:2118–2124.
- Patel R, Nagueh SF, Tsybouleva N, et al. Simvastatin induces regression of cardiac hypertrophy and fibrosis and improves cardiac function in a transgenic rabbit model of human hypertrophic cardiomyopathy. *Circulation.* 2001;104:317–324.
- Buemi M, Allegra A, Senatore M, et al. Pro-apoptotic effect of fluvastatin on human smooth muscle cells. *Eur J Pharmacol.* 1999;370:201–203.
- Blanco-Colio LM, Villa A, Ortego M, et al. 3-Hydroxy-3-methylglutaryl coenzyme A reductase inhibitors, atorvastatin and simvastatin, induce apoptosis of vascular smooth muscle cells by downregulation of Bcl-2 expression and Rho A prenylation. *Atherosclerosis.* 2002;161:17–26.
- Vrtovsnik F, Couette S, Prie D, et al. Lovastatin-induced inhibition of renal epithelial tubular cell proliferation involves a p21ras activated, AP-1-dependent pathway. *Kidney Int.* 1997;52:1016–1027.
- Kreuzer J, Watson L, Herdegen T, et al. Effects of HMG-CoA reductase inhibition on PDGF- and angiotensin II-mediated signal transduction: suppression of c-Jun and c-Fos in human smooth muscle cells in vitro. *Eur J Med Res.* 1999;4:135–143.